



ACOT: Sample Oral Examination Questions

Defence of the case report

The examiners will identify a number of key issues surrounding the condition(s) described in the case report and have a list of questions relating to the pathophysiology, management, drug action and diagnostic criteria. It is expected that the candidate has a thorough knowledge on all these issues.

Short answer questions

The purpose of the short answer questions is to probe the breadth of knowledge of the candidate. It is expected that each question would take approximately one minute to complete.

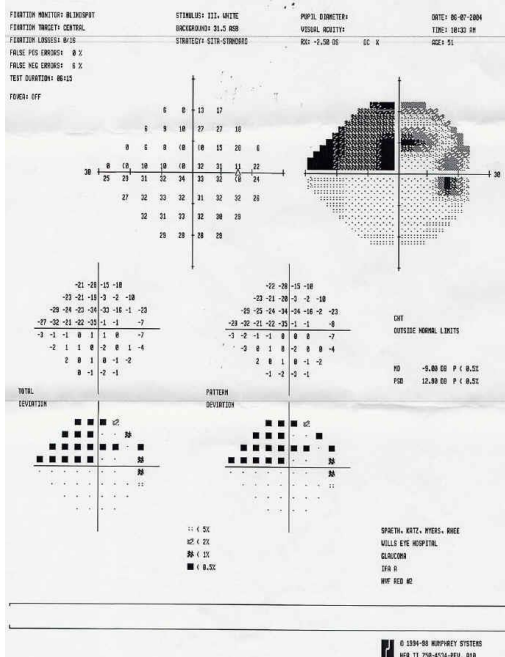
Sample Short Question 1

- (a) When prescribing anti-glaucoma medication, which is considered to have a potential neuroprotective role in glaucoma?
(b) What is the mechanism of action of this drug and the expected drop in intra-ocular pressure?

Sample Short Question 2

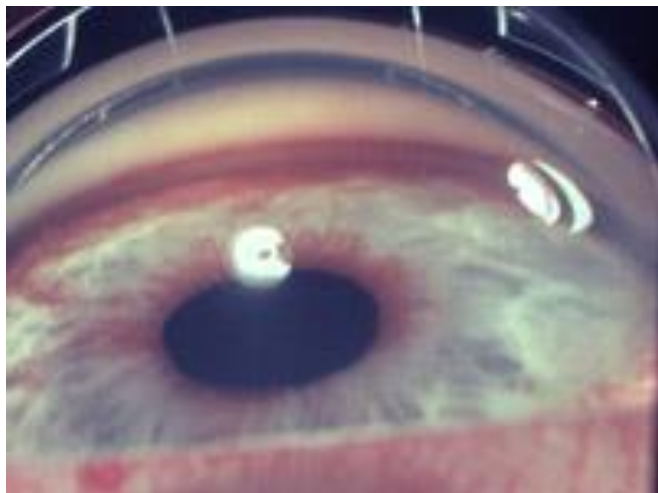
Visual field in one eye: describe the defect, likely anatomical location of the cause and differential diagnosis, OR

Describe the different visual field parameters, e.g. GHT, total and pattern deviation, reliability indices.



Sample Short Question 3

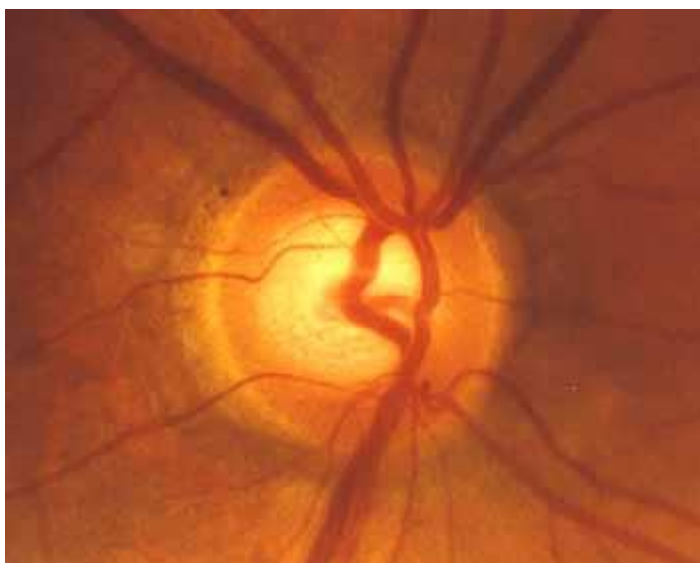A 55-year-old diabetic male complains of poor vision in the right eye. Pressures are 38mmHg in the RE.



- (a) Describe the appearance of the eye.
- (b) Provide the tentative diagnosis and management.

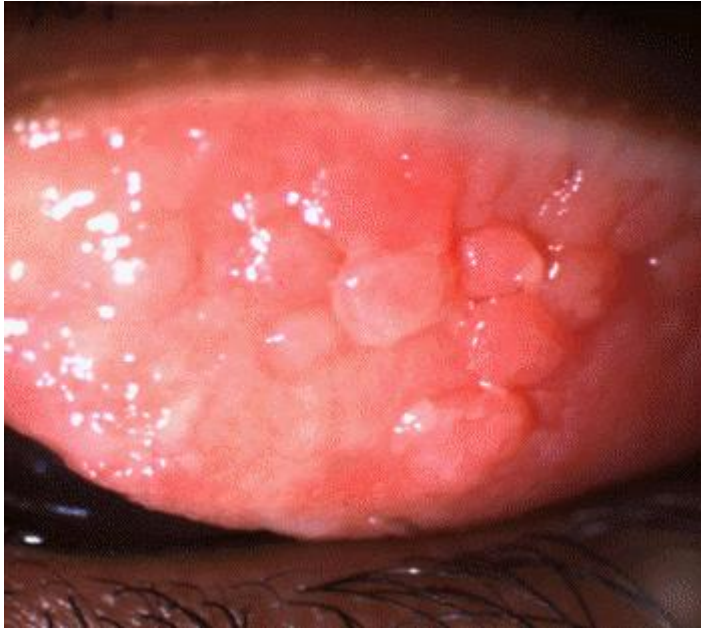
Sample Short Question 4

- (a) Describe the appearance of the optic nerve.
- (b) Provide the tentative diagnosis and management.



Sample Short Question 5

- (a) Describe the appearance of the lid.
- (b) Provide the tentative diagnosis and management.

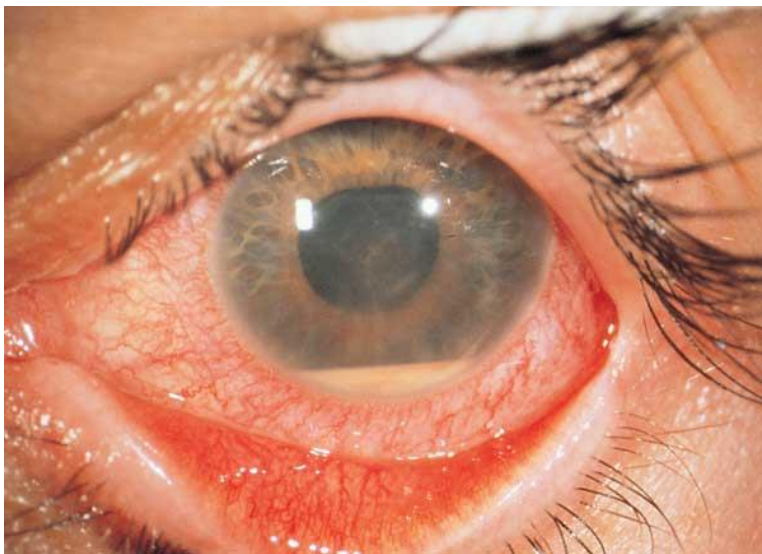

Long answer questions

Long answer questions are designed to probe in depth information. An image would normally be provided and some information relating to the patient from which the image is taken. The candidate would then be expected to seek specific test or diagnostic results or other pertinent information. As the amount of information increases, the candidate is expected to develop a likely diagnosis, differentials, and a management plan that lies within the scope of practice of a therapeutic optometrist. However, a working knowledge of the potential management plans that might be instigated by other health care practitioners is also required. The focus of questions to be chosen in this section will depend upon the topic areas covered by the case reports. Approximately 5 minutes should be devoted to each long answer question.

Question Long 1

A 35-year-old male patient presents with a sore left eye of about a week's duration. He has been using an over the counter topical drops (decongestant) to relieve the redness but the pain has persisted.



- (a) Describe the appearance of the eye.

The candidate should ask for the Visual Acuity: *Given 6/15 (reduced from 6/6) in the affected eye.*

The candidate should ask if he has had this type of pain before: *He remembers multiple episodes over the past few years but the pain/discomfort has not been as bad as this episode.*

The candidate should ask for a description of the anterior chamber: *Given that there is flare and cells were observed (expected given the existence of a hypopyon).*

- (b) Provide a differential diagnosis for the image considering all the additional information. Provide the most likely cause. The candidate may be asked to identify other key test results.

The candidate should ask for IOP: *Given OD 16 mmHg and OS 45 mmHg.*

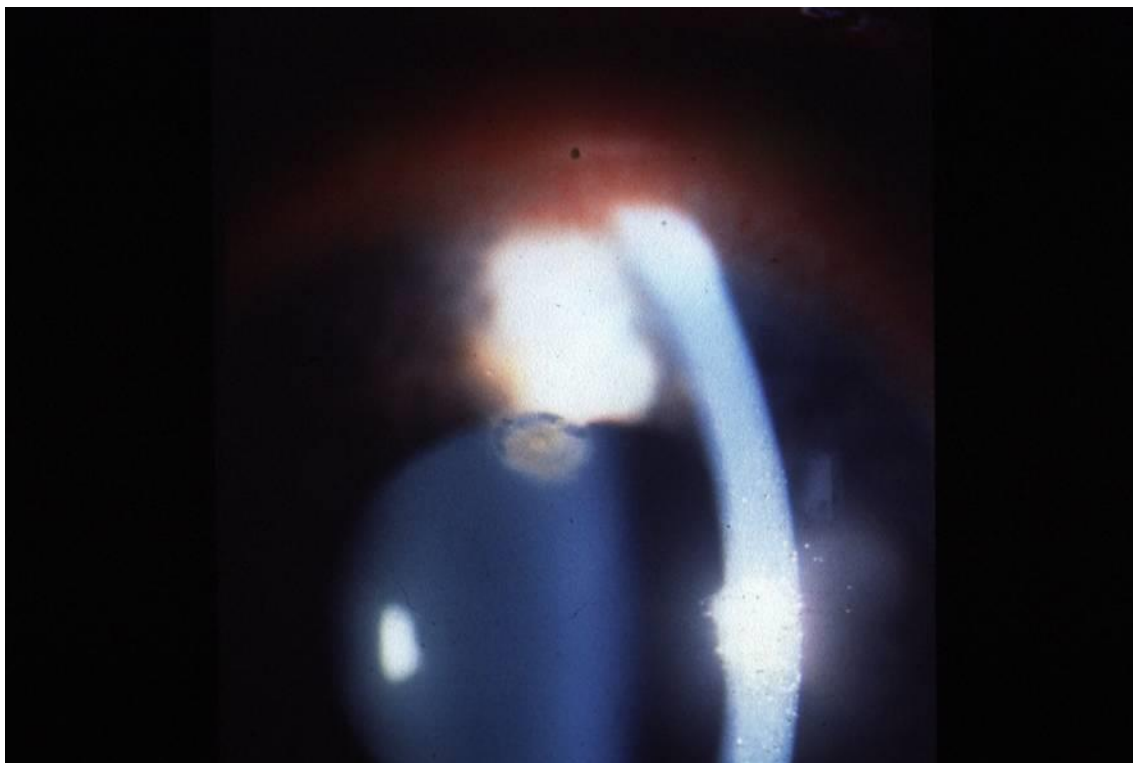
The candidate should ask about systemic conditions such as sore lower back, autoimmune disease: *Given that the patient has a history of ulceration of mucosal surfaces.*

- (c) Why is the intra-ocular pressure elevated in this patient?
- (d) What should the appropriate management be for this patient (non-ophthalmic)?

- (e) Describe an appropriate management plan for this patient that a therapeutic optometrist would provide, and that of an ophthalmologist.
- (f) If you had to initiate treatment to treat the elevated intra-ocular pressure, identify at least two medications that could be used and two that are contraindicated. Explain your answer.

Question Long 2

A 26-year-old male is waiting for your practice door to open at 9.00am. He has a sore watery eye that has worsened overnight. He has a history of wearing his contact lenses in the hot tub.



- (a) Describe the corneal appearance.

The candidate should ask for the Visual Acuity: *Given 6/15 in the affected eye.*

The candidate should ask about the pain level the patient is experiencing: *Given patient is in extreme pain.*

The candidate should ask about the appearance of the anterior chamber: *Given that there is an anterior chamber reaction.*

The candidate should ask about his history of contact lens care: *Given patient is very diligent with the care of his contact lenses and he uses a hydrogen peroxide disinfecting system.*

- (b) Provide a differential diagnosis for the condition and the most likely diagnosis based upon the appearance and additional information above.
- (c) In view of (b) outline the natural progression of this condition and the significance of the bathing behaviour of this patient.
- (d) Outline the appropriate management plan including therapeutic agents that may be used and their mechanism of action. Appropriate testing protocols of the corneal scrape may also be asked.

Acknowledgement – these images were from:

Digital Journal of Ophthalmology (<http://www.djo.harvard.edu/>);
<http://www.onjoph.com/global/beitraege/fingerclubbing/index.html>;
<http://www.uveitis.org/medical/articles/case/Allergy.html>;
<http://www.mdconsult.com/das/pdxmd/media/1206/6120619/large.jpg>;
http://www.bobshowto.com/health-documents/visual_field_test_picture_right.htm;
Dr Erica Fletcher and Russell Lowe